

Efficacy of Ultrasonography in the Diagnosis of Cystic Neck Masses Confirmed By Histopathological Examination

Assist. Lect. Dr. Sarab M. Zeki Radhi (B.D.S, M.Sc.)

sarabmzeki@yahoo.com

University of Baghdad - College of Dentistry

Assist. Prof. Dr. Khairallah Muzhir Gabash (FRCS)

Kha19682000@yahoo.com

Wasit University - Collage of Medicine

Prof. Dr. Lamia H. Al-Nakib (B.D.S., M.Sc.)

lhusein@yahoo.com

University of Baghdad - College of Dentistry

Abstract

Background: Cystic lesion of the neck is one of the lesions that fall under the umbrella of congenital and acquired neck masses. Ultrasonography plays an important role in the diagnosis of these lesions. The aim of this study is to highlight the efficacy of ultrasonography in the diagnosis of cystic lesions of the neck area. **Materials and methods:** 43 patients presented with palpable neck mass were examined clinically and scanned by ultrasonography, these patients were divided into three groups according to the histopathological examination of the cystic lesions, group 1 was 32 patients with thyroglossal duct cyst, group 2 was 8 patients with cervical tuberculous lymphadenitis and group 3 was 3 patients with branchial cleft cyst. FNAC was done and the aspirate sent for cytological, bacteriological and biochemical assessments were done for more confirmation. Plain X ray for the chest, Computed

tomography (CT) if the lesion is deep seated or to detect the primary neoplastic lesion if great suspicion is present.

Results: *The accuracy of ultrasonography in the diagnosis of thyroglossal duct cyst was 94.4%, cervical tuberculous lymphadenitis and branchial cleft cyst were 80%.*

Conclusion: *Despite the need for further radiological investigation like CT scan in some patients, ultrasonography remains the first line investigative tool with high sensitivity and specificity.*

Keywords: *Ultrasonography, Cystic Neck Masses, Histopathology*

Introduction

Neck Masses are any swelling or enlargement of the structures in the area between the inferior border of mandible and clavicle [1]. The patient's age, the location, size and duration of mass are important parameters in the diagnosis [1,2]. However, imaging is essential for accurate diagnosis and pretreatment planning. Cystic masses of neck include a wide range of congenital and acquired lesions. The latter include various inflammatory and neoplastic diseases [2,3].

Detailed case history and systematic clinical examination are fundamental and mandatory steps of clinical assessment. But in some cases, such as chronic inflammation, abscess formation, deep-seated or infected cystic lesion and neoplasms, clinical examination and palpation do not provide complete assessment of the exact origin and nature of swellings; such cases need further diagnostic measures particularly radiological imaging [4,5]. The role of sonography (USG) in evaluation of neck region is becoming increasingly important due to the availability of high frequency probes, which permit visualization of more subtle anatomical and pathological details [1]. It shows the origin of the lesion and differentiates whether it is cystic or solid. [1,5].

Because most lesions in the neck are site-specific, once a lesion has been located, specific ultrasound criteria can be applied to establish the diagnosis. Definite diagnosis was done by fine

needle aspiration cytology (FNAC) and then histopathological examination after surgical excision as a gold standard to compare with ultrasonographic diagnosis [2].

Patients and Methods"

This study was conducted in Surgical and Radiological departments, Al-Karama teaching hospital, Kut city, Iraq. From January 2015 to December 2015, forty three patients presented with palpable neck mass were included in a cross sectional study, their ages range (2- 63) years. Age limitation was not considered and male-to-female ratio was 1: 1.2. Patients were informed about the procedures and a written consent forms were obtained.

Any case did not show cystic lesion on the ultrasonographic image was excluded, thyroid lesion was also excluded.

Clinical history and presentation as well as location permit clinical diagnosis. Imaging specially ultrasonography is considered the method of choice for confirming clinical suspicion.

Imaging:

After provisional diagnosis, patients were subjected to radiological imaging.

1. **Sonographic investigation** of each swelling was carried out in the Department of Radiodiagnosis using linear probe with frequency of 7.5 MHz-10 MHz [6].

The patient were examined in supine position, with neck extended. A small pad placed under shoulder to provide better exposure of the neck [1].

The following features were considered in describing the sonographic images of swelling in accordance with Shimizu et. al. [7]:

- Shape: oval, lobular, round, polygonal, irregular;
- Boundary: very clear, relatively clear, partially unclear, ill defined;
- Echo intensity: anechoic, isoechoic, hypoechoic, hyperechoic, mixed;

- Ultrasound architecture of lesion: homogeneous, heterogeneous;
- Presence of necrosis: eccentric, central;
- Presence of calcification: macrocalcification, microcalcification;
- Posterior echoes: enhanced, unchanged, attenuated.
- Ultrasound characteristic of tissues: cystic, solid, mixed

All sonographic images obtained in this study were checked and reinterpreted by two experienced sonologists

2. **FNAC** done and the aspirate sent for cytological, bacteriological and biochemical assessment.

3. **Plain X ray for the chest.**

4. **Computed tomography (CT)** if the lesion is deep seated or to detect the primary neoplastic lesion if great suspicion is present.

After all those investigations a primary diagnosis have been reached and the patient scheduled for surgery, an informed consent was taken and the surgeon explained some important points of the surgical procedure for the patient and/or his close relative, to be underwent for excisional biopsy to confirm the primary diagnosis by histopathological examination of the specimens.

The obtained results were tabulated and statistically analyzed and finally the diagnostic efficacy of Ultrasonography was expressed in terms of sensitivity, specificity, positive predictive value, negative predictive value and accuracy.

Results

A forty-three patients (n=43) with neck masses were included in this study (male =19, female =24), their ages range (2-63 years). The final diagnosis divided these patients into three groups, in the first group there are 32 patients with thyroglossal duct cyst (TDC=32), in the second group comprise eight patients with cervical tuberculous lymphadenitis (CTLA=8), and in the third group there are three cases diagnosed as branchial cleft cyst (BCC=3).

Table 1: Frequency distribution of the sample according to lesion type

Disease	Number of patient	Percentage
TDC	32	74.4
CTLA	8	18.6
BC	3	6.98

Thyroglossal duct cyst(TDC):

Thirty-two patients diagnosed as cases of TDC, 18 males and 14 females. Their ages range from (2-25) year. Twenty-eight patient present with asymptomatic midline neck swelling and the other 4 patients present with acutely inflamed midline neck swelling.

The site was characterized in relationship to the hyoid bone, 22 patients (69%) had infra-hyoid TDC and the remaining 10 patients (31%) had a lesion located at or just above the level of hyoid bone.

Sonography of the TDC lesions was mostly showing round to oval anechoic cystic lesion with clear border and posterior enhancement. (Table 2)(Figure 1)

FNAC: TDC is well diagnosed by clinical and sonological investigation. FNAC may not be necessary in patients undergoing surgery because the lesion will be excised and send for histopathological examination.

Histopathological examination(HPE): after a Sistrunk procedure excisional biopsy is sent for histopathological examination that showed cystic lesions lined either by pseudostratified columnar or cuboidal epithelium, the walls showed cholesterol crystals in only 2 patients, thyroid follicles in 10 lesions and lymphocytic tissues in 7 patients.

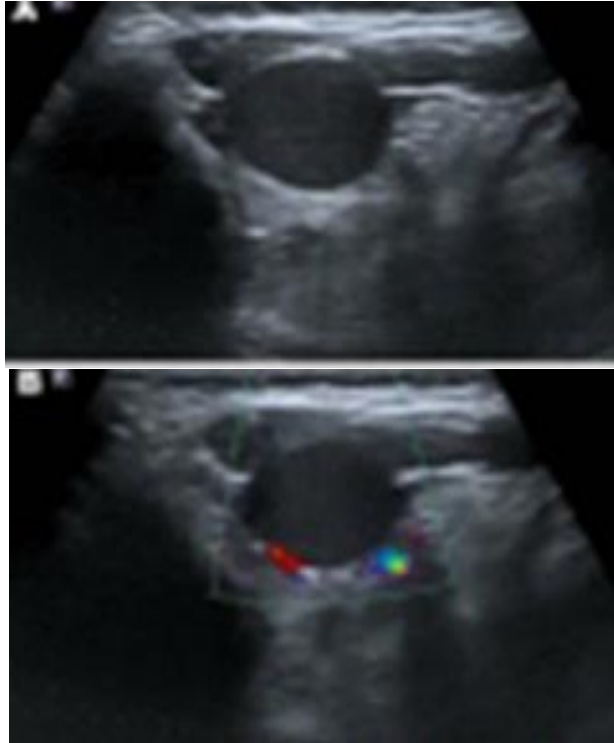


Figure 1:A. Grey scale Sonography of the submental triangle shows an oval mass with well-defined margin and hypoechoic echotexture, B. Doppler sonography shows avascular cystic lesion.

Cervical tuberculous lymphadenitis (CTLA):

In this study 8 patients diagnosed as cases of tuberculosis of the cervical lymph nodes, 6 of them were females and 2 were males, their ages range from (25-44) years. All the patients have the clinical manifestations of tuberculosis like; fever, night sweating and weight loss. The swelling was tender in only one patient. On chest X-ray they showed no sign of pulmonary TB. On laboratory investigation all the patients had elevated ESR and elevated WBC count. On sonographic examination each cervical mass was of multiple matted lymph nodes (LN) with absence of hilum.

Site: Seven of the patients have multiple swelling, three of them have bilateral swelling, and the other one has single swelling.

Sonographic features of the lesions are mostly round hypoechoic mixed but homogeneous lesion with clear border and posterior enhancement as shown in table 2. The TLA appeared multiple and matted with absent hilum as shown in (fig. 2)

Doppler US reveals hilar vascularity.

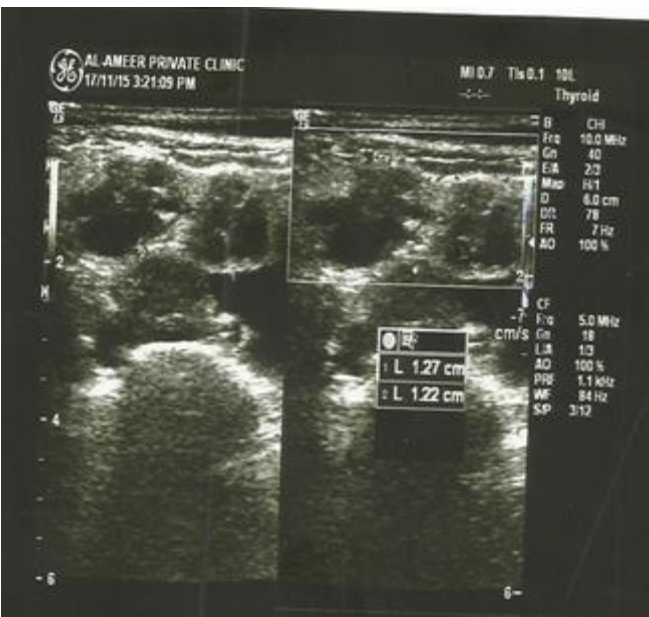

Figure 2: Multiple enlarged right supraclavicular matted LAP appears rounded with very thin fatty hilum.

FNAC: 75% of patients show nonspecific inflammatory tissues with degenerated material and hemorrhagic background.

Other 25% show pus like necrotic caseous material, lymphocytic cells, epithelioid cells and scattered giant cells (cytopathological feature of chronic specific TB lymphadenitis).

Excisional biopsy: histopathological examination shows the typical picture of tuberculous lesion (granuloma and caseation necrosis).

Branchial cleft cyst (BCC):

Three female patients proved to have branchial cyst by histopathological examination, two of them were young (thirties) and they presented with swelling along the upper third of anterior border of sternocleidomastoid muscle on the right side of the neck. The third case was a 63 years old lady presented with left side neck swelling in the upper 2/3 of the neck. The swellings was fluctuant but not tender. Laboratory investigations were normal for all the patients.

x-ray of neck and chest were nonspecific.

Sonographic features of the lesions were round to oval, homogeneously anechoic cystic lesion with posterior enhancement and well-defined borders as shown in table 2 and figure 2.

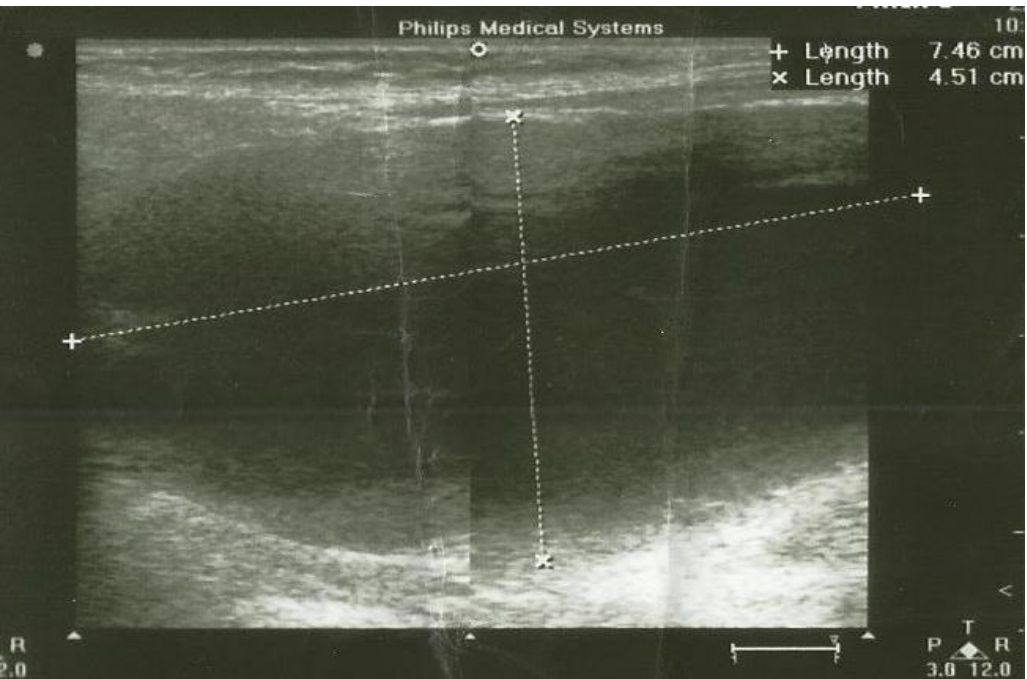


Figure3: Sonography of a 63 years old female shows a cystic lesion in posterior triangle of the neck.

CT scan: For the old lady of 63 years old CT examination with contrast revealed well defined thin wall uninocular purely cystic lesion oval shaped measuring 5x7cm in dimentions occupying the left side of the neck displacing left thyroid lobe anteromedially, left carotid sheath medially and trachea to controlateral side the cyst is deeply seated forming indentation of oropharynx and abutting the posterior part of the trachea giving an impression of benign cystic lesion.

Table 2: Sonography of the lesions types comparison according to Shimizu criteria

Criteria	Feature	TDC percentage	CTLA percentage	BCC percentage
Boundary	Very clear	90.625	100	100
	Relatively clear	6.25		
	Partially unclear	3.125		
Shape	Oval	31.25	25	33.3
	Round	59.375	75	66.7
	Tubular	9.375		
Echo-intensity	Anechoic	56.25		100
	Hypo + Anechoic	43.75	100	
Ultrasound architecture of lesions	Homogeneous	93.75	100	100
	Heterogeneous	6.25		
Posterior echoes	Enhanced	100	100	100
Ultrasound characteristic of tissues	Cystic	100		100
	Solid			
	mixed		100	
Presence of necrosis	centric			
	eccentric	6.25	100	

FNAC: revealed necrotic cells with abundant lymphoid and inflammatory cells.

Histopathological examination (HPE): After total excision of a unilocular cyst the specimen submitted for histopathological examination that revealed abundant lymphoid tissues with germinal centers with focal fibrosis, concluding that the branchial cyst is the most probable diagnosis.

Statistical analysis for the efficacy of sonography:

The efficacy of sonography on different type of groups of cystic swelling of the neck on the term of sensitivity , specificity, PPV, NPV and accuracy as in table 3.

Table 3: Diagnostic indices of sonographic diagnosis of each group by percentage

Groups	Sensitivity	Specificity	PPV	NPV	Accuracy
TDC	93.75	100	100	66.67	94.4
TLA	100	66.67	88.89	100	80
BCC	66.67	100	100	66.67	80

Snography in diagnosis of TLA has highest sensitivity, TDC & BCC have highest specificity and TDC has highest accuracy

Discussion

Neck swelling is very common clinical condition. Proper management of this condition mandate full assessment of the lesion with different approaches [5].Clinical history and presentation as well as location permit clinical diagnosis. US is considered the method of choice for confirming clinical suspicion. All the patients in the present study underwent sonographic examination according to Shimizu et al.'s criteria then comparison between different groups on the base of sensitivity, specificity, PPV, NPV and accuracy was done. Shimizu et al.'s criteria were sufficient to

differentiate between truly cystic lesion and other solid or mixed ones.

All the lesions had posterior enhancement and this gives the impression of being cystic [8]. While other sonographic features like the location of the lesion, its multiplicity and the state of surrounding tissues enable us to further differentiate and decrease the wide range of differential diagnosis [8.9.10].

Thyroglossal duct cyst:

TDC can be diagnosed clinically by asking the patient to protrude his tongue the cyst will move upward or to the side which is a diagnostic test for TDC, the role of sonologist is to confirm the clinical diagnosis and identify the presence of thyroid gland [11.12.13].

In addition, a preoperative sonographic examination is important to confirm whether a TDC is accompanied by any unexpected complications, such as a solid component or fistula [12,14]. In the present study no patient had been shown these complications.

Ahuja et. al. [12] stated that the differential diagnosis of TDC in adults includes dermoid cyst, branchial cleft cyst, lymphadenopathy, and a cystic nodule arising from the thyroid gland. In this study lesions arising in the thyroid gland which is easily diagnosed by US is excluded, so the next step is to exclude dermoid cyst that in US it resembles TDC so the differentiation between them is quite difficult, nevertheless the preoperative differentiation between them is not necessary since both are treated surgically by Sistrunk procedure and the definite diagnosis is made by histopathological examination.

If the TDC is off midline it should be recognized from lymph node, also this was done sonographically . The normal lymph nodes are multiple, hypoechoic and have central hilum which is quite different from TDC, the problem is with lymph node which have cystic necrosis either centric and this is the feature of malignancy or eccentric which is the feature of tuberculous lymphadenitis. In addition to that tuberculous lymph nodes appear matted and show perinodal tissue edema that are the characteristic features of tuberculous lymphadenitis [6.12.15].

It's difficult to differentiate between TDC & BCC sonographically since both are true cystic lesions, and this is done by the clinical presentation particularly the lesion site; the branchial cysts most commonly occur in a latero-cervical location, and then confirmed by histopathological examination [11.12].

Tuberculous lymphadenitis

Although typical US features exist, none are pathognomonic and CTLA cannot be diagnosed merely with US. For example, the metastatic nodes from papillary thyroid carcinoma may mimic tuberculous nodes under US because of the shared features of cystic necrosis. Moreover, it is difficult to differentiate between sprinkled calcifications of papillary thyroid carcinoma metastases and caseative necrosis of tuberculous nodes when punctate echogenic foci are seen on US. US assisted FNA & CNB greatly increases the diagnostic accuracy of US [4,16]

Brachial cleft cyst

As per King's criteria any cyst arising outside the midline of the neck and having lymphoepithelial characteristics should be regarded as a branchial cyst [17].

Differential diagnosis of cystic lesion in the posterior triangle is cystic hygroma and this was supported by FNAC. Ahuja et al 2000 [8] stated that cystic hygromas sonographically were seen as multiple, compressible cysts of varying sizes, with thin walls and intervening septa that infiltrate between and around neurovascular structures which doesn't matching the sonologic appearance of the cases in this study.

Conclusion

Owing to the high sensitivity and accuracy in diagnosis of cystic lesion of the neck, sonography appears as an excellent first line investigative tool. Despite the need for further radiological examination like CT, sonography remains the best due to its noninvasiveness, feasibility and reliability.

References

- [1] Thapa N., "Ultrasound in the Diagnosis of Neck Masses", Journal of Nepal Health Research Council Vol.4 No.1 April 2008.
- [2] ERIC SCHWETSCHENAU and DANIEL J. KELLEY, "The Adult Neck Mass", Am Fam Physician. 2002 Sep 1; 66(5):831-839.
- [3] Mahesh Kumar Mittal, Amita Malik, Binit Sureka, Brij Bhushan Thukral, "Cystic masses of neck: A pictorial review", Indian J. of Radiology & Imaging: Year: 2012, Volume 22, Issue 4, Page 334-343
- [4] Chintamaneni Raja Lakshmi, M. Sudhakara Rao A. Ravikiran, Sivan Sathish, and Sujana Mulk Bhavana: "Evaluation of Reliability of Ultrasonographic Parameters in Differentiating Benign and Metastatic Cervical Group of

- Lymph Nodes", ISRN Otolaryngology; Volume 2014 (2014), Article ID 238740, 7 pages.
- [5] Chandak R , Degwekar S, Bhowte RR, Motwani M, Banode P, Chandak M, and Rawlani S., "An evaluation of efficacy of ultrasonography in the diagnosis of head and neck swellings", *Dentomaxillofac Radiol.* 2011 May; 40(4): 213–221.
- [6] K.B. Gupta¹, Ashok Kumar, Rajiv Sen, Jyotsna Sen and Manish Verma, "Role of Ultrasonography and Computed Tomography in Complicated Cases of Tuberculous Cervical Lymphadenitis", *Indian J. of Tuberc.* 2007; 54:71-78.
- [7] Shimizu M, Ussmuller J, Hartwein J, Donath K., "A comparative study of sonographic and histopathologic findings of tumours lesions in the parotid gland", *Oral Surg. Oral Med Oral Pathol Oral Radiol Endod* 1999; 88:723–737. [PubMed]
- [8] Anil T. Ahujaa, Ann D. Kinga and Con Metrewelia, "Second Branchial Cleft Cysts: Variability of Sonographic Appearances in Adult Cases", *AJNR* 2000 21: 315-319.
- [9] Benjamin J. Ludwig¹, Jimmy Wang¹, Rohini N. Nadgir, Naoko Saito, Ilse Castro-Aragon¹ and Osamu Sakai¹. "Imaging of Cervical Lymphadenopathy in Children and Young Adults", *AJR* November 2012, Vol. 199, No. 5.
- [10] Shahrzad Mohseni, MD, Abolfazl Shojaiefard, MD, Zhamak Khorgami, MD, Shahriar Alinejad, MD, Ali Ghorbani, MD, and Ali Ghafouri, MD., "Peripheral Lymphadenopathy: Approach and Diagnostic Tools", *Iran J Med Sci.* 2014 Mar; 39(2 Suppl): 158–170.
- [11] M. Valentino, C. Quiligotti, A. Villa, and C. Dellafiore. "Thyroglossal duct cysts: Two cases", *J Ultrasound.* 2012 Sep; 15(3): 183–185.

- [12] Anil T. Ahuja, Ann D. King, Walter King and Con Metreweli, "Thyroglossal Duct Cysts: Sonographic Appearances in Adults", AJNR 1999 20: 579-582 HEAD AND NECK
- [13] Sladjana Petrović, Dragan Petrović, Zoran Pešić, Predrag Kovačević, "Sonography of Congenital Neck Masses in Children", Series: Medicine and Biology Vol.12, No 3, 2005, pp. 164 – 169.
- [14] Naoki Kutuya and Yoshihisa Kurosaki, "Sonographic Assessment of Thyroglossal Duct Cysts in Children", J Ultrasound Med 2008; 27:1211–1219 • 0278-4297/08/\$3.50
- [15] Sorin M. Dudea, Manuela Lenghel, Carolina Botar-Jid and Dan Vasilescu, "Ultrasonography of superficial lymph nodes: benign vs. malignant", Review Med Ultrason 2012, Vol. 14, no. 4, 294-306
- [16] Chen-Han Chou, Tsung-Lin Yang and Cheng-Ping Wang, "Ultrasonographic Features of Tuberculous Cervical Lymphadenitis", Journal of Medical Ultrasound ,Vol. 22, Issue 3, September 2014, Pages 158–163
- [17] Khairallah M. Gabash, "Rare clinical presentation of Branchial cyst: a case report", Medical Journal of Babylon, Vol. 9: 2, 2014.

فعالية الفحص بالموجات فوق الصوتية في تشخيص التكيسات العنقية وتأكيده بالفحص النسيجي المجهرى

د. سراب محمد زكي راضي

sarabmzeki@yahoo.com

جامعة بغداد – كلية طب الأسنان

ا.م.د. خير الله مزهر غباش

Kha19682000@yahoo.com

جامعة واسط – كلية الطب

أ.د. لمياء حامد النقيب

lhusein@yahoo.com

جامعة بغداد – كلية طب الأسنان

المستخلص

الأمواج فوق الصوتية تلعب دورا مهما في تشخيص التكيسات العنقية التي قد تكون ولادية او مكتسبة وذلك لان لها القدرة على تحديد موقع وحجم الكيس بدقة عالية بالإضافة الى الصفات الداخلية للكيس.

في هذه الدراسة يتركز هدفنا في القاء الضوء على كفاءة الأمواج فوق الصوتية في تشخيص مثل هذه الافات.

على مدى عام 43 مريضا قد تم فحصهم سريريا و بالامواج فوق الصوتية . وطبقا للفحص النسيجي تم تقسيمهم الى ثلاثة مجاميع : المجموعة الأولى وتضم 32 مريضا مصابين بالكيس الدرقولساني اما المجموعة الثانية فتضم 8 مرضى مصابين بالتهاب العقد اللمفاوية العنقية التدرني المتكيس وفي المجموعة الثالثة كان هناك 3 مرضى مصابين بالاكياس الخيشومية .

كانت دقة السونار في تشخيص الاكياس الدرقولسانية 94.4% اما دقته في تشخيص كلا من التهاب العقد اللمفاوية التدرني و الاكياس الخيشومية فقد كانت 80% .
على الرغم من الاستعانة بالأشعة المقطعية (المفراس) في بعض الحالات للوصول للتشخيص الصحيح الا ان الفحص بالامواج فوق الصوتية هو الخيار الاول وذو كفاءة ودقة عاليتين كما استخلص من هذه الدراسة.
الكلمات المفتاحية: جهاز الأمواج فوق الصوتية التشخيصي، التكيسات العنقية، التحليل النسيجي.